



Pediatric Feeding and Dysphagia Newsletter

Dear Fellow Feeders,

Happy 2005. In this issue we explore sensory issues with Lori Overland from Talk Tools, what it means to have a laproscopic nissen fundoplication, and we get an understanding of congenital lactose intolerance. As always we learn from a fascinating case and the latest research. We love to hear from you! Please email with comments, questions, suggestions, or ideas.

- Krisi Brackett MS SLP/CCC, feedingnews@earthlink.net

**Pediatric Feeding and
Dysphagia Newsletter**
Hiro Publishing
www.feedingnews.com

Volume 5, number 3

January, 2005

	<h2>Food for Thought</h2>
<p>By Lori L. Overland, M.S., CCC/SLP</p>	

Many feeding aversions don't exist simply in and of themselves. They're often secondary to sensory or motor issues.

Imagine walking into your home, smelling a turkey cooking in the oven. Your stomach growls in response, and you start to salivate. You look forward to an enjoyable experience and can't wait for dinner.

But for many of the clients we work with, mealtimes are anything but enjoyable. For some children, in fact, they're absolutely frightening.

Over the years, I've received countless referrals for children who reportedly had "behavioral feeding aversions". The vast majority of these clients, however, had feeding aversions or "behavioral feeding issues" secondary to sensory or motor issues.

Many times, strict behavioral intervention programs may not recognize or treat the sensory or motor etiology of feeding disorders. But to help these children, we need to evaluate the true causes of the "feeding disorder" and use a team approach. This team may include physicians (i.e., a pediatrician, developmental pediatrician, family doctor, gastroenterologist, neurologist, psychologist), an occupational therapist, a speech-language pathologist and a nutritionist. Individually, the clinicians should address the areas that directly lie within their areas of expertise.

For example, physicians must address the underlying medical issues that interfere with a client's ability or willingness to eat by mouth. The occupational therapist should address underlying sensory concerns that affect the child's ability to function. And the speech-language pathologist, while contributing to the understanding and treatment of oral sensitivities, focuses on the oral motor skills that support safe and effective feeding. Together, the occupational therapist and speech-language pathologist help develop a sensory diet that respects a client's taste, texture and temperature preferences. In concert with this, the nutritionist designs a diet that provides adequate caloric and nutritional intake while respecting a client's sensory needs.

When all these professionals come together, they can address the complex problems that often underlie "behavioral feeding aversions" as the following case studies show.

Special Points of Interest:

- Current information
- New products
- Research and publications
- Education

Editorial assistance provided by Elizabeth Crais Ph.D. CCC SLP, Division of Speech and Hearing Sciences, UNC-Chapel Hill and Cathy Fox MS OTR/L, Private Practice, Frederick, MD

Inside this issue:	
Food for Thought	1-2, 7
Laprosopic Fundoplication	3-5, 7
Q&A: Lactose Intolerance	6
Case by Case	8-9
On the Research Front	9-10

(Continued on page 2)

Jason is a 5-year-old boy with a diagnosis of pervasive developmental delay. He is extremely hypersensitive to high-pitched sounds. As his mother begins the preparations for dinner, Jason puts his fingers in his ears and begins rocking back and forth. The hum of the microwave and the buzz of the blender increase the intensity of Jason's protests.

Jason screams as his parents try to put him in a chair for dinner. Although the child's pediatrician suggests he has behavioral issues, a more accurate assessment may be that Jason's hearing sensitivities are so significant that the kitchen is an unpleasant place for him.

Jason's initial intervention plan included intensive sensory integration therapy, as well as auditory integration training. Meals were prepared while Jason was at school. Extraneous environmental noise was reduced during mealtime, and metamusic was played at a low level. In addition, the family ate in the dining room rather than in the kitchen, since the visual and auditory environment was less stimulating to Jason. As his hearing sensitivities decreased, so did the "behavioral issues" that had negatively affected mealtime.

Sarah is a 10-month-old baby girl. Initially, she had trouble with bottle-feeding, which required several nipple and formula changes. She has a history of gastrointestinal reflux, which was addressed with position changes and thickened formula. Eventually, it resolved with medication.

She also was a difficult baby to calm and required complicated routines for bathtime, dressing/ undressing and bedtime. At 6 months, rice cereal was introduced into her diet. Sarah gagged and spit up. Although her parents tried a variety of baby cereals, fruits and vegetables over the next few months, Sarah's reaction was generally the same.

Her parents were advised to give her time; doctors assured them that Sarah would get used to food. And they weren't overly concerned because the child's weight continued to stay on the charts. But her parents were frantic.

Through a sensory diet program, we discovered that Sarah's reaction to baby food was different if we changed the temperature of the food. For example, we put applesauce in the freezer 15 minutes before we presented it to her. Cold temperatures often increase awareness of food in the oral cavity, and, in turn, provide increased information to the oral musculature.

In Sarah's case, the cold temperature enhanced the input of the bland, lukewarm baby food. In addition, the increased information encouraged lip closure on the spoon and facilitated more effective tongue retraction to move the bolus back in the oral cavity. Sarah actually enjoyed the mealtime experience.

Alexandra is a 2-year-old girl with Down syndrome. She reportedly did "fine" on a bottle and with pureed foods. But when solid foods were introduced, at approximately 9 months, Alexandra had repeated incidents of gagging and choking.

Initially, she would try any solid foods presented, but she reportedly became a picky eater. By 15 months, she would only eat crunchy, salty foods, such as Goldfish and crackers, and pureed foods. She would sometimes put a solid food she deemed acceptable into her mouth, suck on it and push it out with her tongue.

As I observed Alexandra eating, I noted that her primary pattern continued to be a suckle with pureed foods and solid foods. She explored other high-taste foods by suckling to experience the flavor and then pushing them out of her mouth with her tongue.

I suspected that Alexandra was afraid to eat solid foods. She didn't have the motor skills to chew food effectively because of low muscle tone, as well as reduced strength and mobility in her jaw, lips, cheeks and tongue.

Alexandra's initial therapy program focused on teaching her to chew and enabling her to handle solid foods safely. We accomplished this by changing the size, shape and presentation of the food bolus, while continuing to respect Alexandra's taste preferences. As Alexandra learned to chew, other food textures became safe and acceptable to her, not just highly flavored, salty foods.

In all of these case presentations, sensory and motor limitations contributed significantly to the "feeding aversion". Families and therapists frequently give children with special needs foods they don't have the motor skills to handle or foods that don't address their sensory deficits. Children often respond by gagging, choking and throwing up. The subsequent learned reaction is to refuse to eat these foods.

Well-meaning therapists and families are so concerned with nutrition that they miss the underlying issues that limit a child's ability or willingness to eat. The practice of "force feeding" clients is another factor that contributes to behavioral feeding problems. The message we give children is "I am bigger than you and I can make you eat". The result is a lack of trust in the therapist or caretaker. And in my experience, force-feeding rarely provides a long-term solution to making mealtimes safe and enjoyable.

Our clients cannot always communicate their needs effectively, and we may miss subtle communication attempts, such as Jason covering his ears to indicate his discomfort with the noise during meal preparation. As these case studies

(Continued on page 7)

Laparoscopic Nissen Fundoplication in Children: Is this a better procedure?

By Lynne D. Farber RN, MSN, CPNP, Clinical Instructor Pediatric Surgery, North Carolina Children's Hospital

Minimally invasive surgery has become the new operative standard in pediatric surgery. As technology advances and surgical techniques are refined, the goal of permitting the smallest degree of cutting, blood loss, and suffering is achieved. In other words, the objective is to preserve the child's body integrity while achieving optimal treatment for many surgical conditions, including Gastroesophageal Reflux Disease (GERD). While this goal is ideal, one may question whether there is a better long-term result when using this new technology?

GERD is a condition where stomach acids flow backwards into the esophagus over time and can cause the area to become painful and inflamed. The esophagus is the food pipe or pathway that food travels to reach the stomach. The esophagus may be unable to tolerate the acid from the stomach, and become damaged. The stomach is designed to contain acid and enzymes, and functions to break down food so that it can enter the intestines. Children with GERD soon associate feedings with pain and irritation, and begin to lose weight as their intake decreases. If not medically managed by acid blockers or medications that prevent acid reflux, these children may be unable to take in enough food to stay healthy. This inability to grow into a healthy child is termed *failure to thrive*. Other symptoms of GERD are recurrent vomiting, regurgitation, irritability, poor weight gain, difficulty swallowing, feeding refusal, aspiration pneumonia, other upper airway symptoms, apnea and Apparent Life Threatening Events (ALTE).¹

Acid may be able to enter the esophagus because the one-way valve into the stomach does not function properly. The Lower Esophageal Sphincter (LES) usually opens when we eat or swallow. If we are not eating, the LES should remain shut to keep the acid in the stomach. A nissen fundoplication is a procedure that prevents acid from rising into the esophagus by reconstructing this one-way valve or LES.

The laparoscopic fundoplication is a technically challenging surgery that requires a skilled pediatric surgeon.¹ The degree of difficulty increases as the size of the patient decreases.² Most surgeons experience the majority of their overall complications in their first 60 cases,³ which subsequently decrease as their experience increases. The time to perform the surgery also significantly decreases as the surgeon's skill increases. The recurrence rate in adults ranges between 2-17%.⁴ In children, the recurrence rates cited range between 0%,⁵ to as high as 15%.⁶ Of note, a recent study reports that the laparoscopic fundoplication in children with neurologic impairments has the same advantages with far fewer complications than are expected in adults.^{7,8}

Preoperative tests

Most surgeons will request that an upper gastrointestinal x-ray be performed in order to confirm correct esophageal and intestinal anatomy. It is important to rule out a congenital condition called malrotation. This x-ray allows the surgeon to examine the pathway that food travels from the esophagus, stomach and small intestine after a child swallows a special contrast (barium). Malrotation occurs in 1:500 children and is caused by the failure of the intestines to rotate to their normal

Laparoscopic Nissen Fundoplication in Children: Is this a better procedure? Continued

position during fetal development. A major complication of this condition could involve twisting of the bowel or *volvulus*, which can be a life-threatening event. It is important for the surgeon to know that a child can swallow and that the stomach empties normally before the antireflux surgery is attempted.

A pH probe test may also be requested before surgery to determine if the cause of a child's respiratory symptoms or regurgitation is due to GERD. This is an overnight test that documents how often acid enters the esophagus and how long it stays there. It is important that all medication that prevents reflux be stopped five days before this test is done so as not to mask the results. The pediatric surgeon may also order a gastric emptying scan, which will show if a child's stomach empties properly.

Most children can be brought to the hospital the same day as the procedure provided that these tests have been completed beforehand, and reviewed by the surgeon. If nutrition has been an issue, it is important to get a dietary consult during the hospital stay. If the patient also received a gastrostomy tube for feeding or medications during the surgery, a social worker will usually meet with the family to arrange a home health company to deliver supplies to the home after discharge from the hospital.

The Procedure

It is extremely important that the surgeon and anesthesiologist are experienced in the care of children. A parent may ask the surgeon how many cases he or she has performed and if board certified in pediatric surgery.

Laparoscopic surgery involves making small incisions to accommodate small instruments or tubes called "trocar" (figure 1). These trocars create a path for special surgical instruments and a laparoscope. The laparoscope is an instrument that is inserted through the abdominal wall that gives the surgeon a view of the operative area on a viewing screen. The use of small tools and the laparoscope to repair the muscle that separates the stomach and esophagus is the *laparoscopic fundoplication*.

The standard port placement is depicted in figure 2. Five 5mm ports are used in most of the laparoscopic procedures for children who weigh more than 10kg². During the procedure, the surgeon raises the liver to uncover the connection between the stomach and esophagus. The top part of the stomach *fundus* lies on the left side of the esophagus. The surgeon wraps the stomach around the back of the esophagus until it meets in front. The wrap is sutured so it stays in place. It is often compared to a buttoned shirt collar where the collar is the wrap and the neck is the esophagus. This wrap allows food to enter the stomach, but prevents acid from flowing back up into the

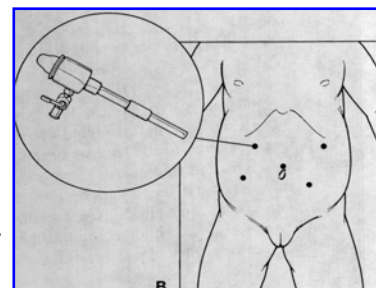


Figure 1

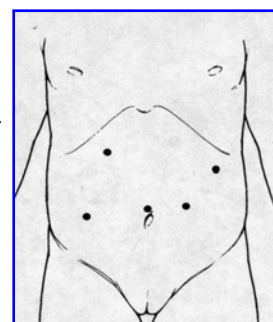


Figure 2

or

Laparoscopic Nissen Fundoplication in Children: Is this a better procedure?

Continued

esophagus. Wraps can be partial or complete. A nissen fundoplication is a complete wrap or 360-degree wrap.

Post-Operative Care

If the child receives a gastrostomy tube during surgery, the caregivers will usually be instructed to "vent" it every 2-3 hours to allow gas to exit the stomach. During the first several weeks or months following the procedure, a child usually cannot burp due to swelling from the wrap, and therefore "venting" is an important comfort measure. If the child has been taking pain medication, they will probably need a laxative to help them avoid constipation. Most children can start their liquid diet on the day after surgery. They will be instructed to follow a pureed or soft mechanical diet for one month to avoid chunks of food getting stuck in their esophagus. This is also known as the "no chunk diet". The swelling will usually resolve in a few weeks, and the diet can be gradually advanced to normal. The surgeon will usually allow the child to return to school and activities in two weeks or after their postoperative checkup.

Results from surgery

Laparoscopic nissen fundoplication is of merit in children who require antireflux surgery. The long-term results are either comparable with traditional open surgery⁸ or improved^{2,9}. There are also other potential benefits which include: less pain, earlier extubation, shorter postanesthesia room stays, shorter durations of chest physiotherapy, fewer intensive care unit admissions, quicker time to resume baseline feedings, and overall decreased length of stay.¹⁰

A recent study⁵ reported that children with difficult-to-treat chronic respiratory symptoms should be evaluated for GERD. The eradication of reflux allowed the children's pulmonologist to effectively manage the children's pulmonary problems and prevent chronic and/or life threatening complications. There were no reported recurrences of reflux 12 months after the surgery and no one experienced a major surgical complication.

Laparoscopy spares the child from a longer abdominal incision associated with an "open procedure". There is also data comparing laparoscopic and open procedures showing that children started on feedings earlier (approx 1 day vs. 3 days) and reached their baseline rate of full feedings earlier¹¹. An additional study⁹ suggested that the laparoscopic antireflux procedure was a benefit in children requiring less pain medication, advanced to regular feedings earlier, and were discharged earlier. All of these benefits support its continued use and acceptance as the procedure of choice for those clinicians who have access to experienced laparoscopic pediatric surgeons.

1. Schier F. Indications for laparoscopic antireflux procedures in children. *Semin Laparosc Surg*. Sep 2002;9(3):139-145.
2. Phillips J. Laparoscopic Fundoplication. In: Mattei P, ed. *Surgical Directives: Pediatric Surgery*. Philadelphia: Lippincott Williams and Wilkins; 2003:251-256.

(Continued on page 7)

Question and Answer: Our questions are answered by Paul Hyman, MD Medical director of Pediatric Gastroenterology, University of Kansas Medical Center.

Are infants ever lactose intolerant?

Congenital lactase deficiency with normal histology has been reported a couple of times. It is exceedingly rare. On the other hand, acquired lactase deficiency is common...every time you get rotavirus it destroys the mature villus tips and so you have a transient lactase deficiency. In other conditions there may be chronic inflammation resulting in villus atrophy and secondary lactase deficiency: celiac disease, protein allergy, microvillus inclusion disease, etc. All the soy formulae and allergy formulae are lactose free but no one marketed that issue until Lactofree.

If an infant has a gastrointestinal allergy to a protein component of formula, there is commonly a secondary lactase deficiency. However, it makes no sense to treat a child with milk protein allergy with a whole protein formula that is lactose free. It makes more sense to treat with a protein hydrolysate and a lactose free formula.

Last week I was at a meeting with Professor John Kerner, nutrition expert from Stanford, who spoke about milk allergy. He stated that switching from milk protein to soy protein was a bad idea for GI allergy, because the injured GI tract is more likely to permit the development of soy sensitivity than a healthy GI tract. He said go right to a hydrolysate (partially digested proteins).



I am a Speech Pathologist who has been treating babies (0-3) with feeding disorders for several years. I recently began to see a 3 year old who has a g-tube, but periodically has episodes of emesis of "golden bile". During these periods he is unable to tolerate even his tube feeding, does not sleep, and has this awful emesis. Any suggestions? We can't find info as relates to the little ones let alone treatment options.

Marcia A. Kirby, MA CCC-SLP

Dear Marcia,

Your history is a little sketchy:

Are you saying that there is a 3 year old with food refusal who is well for weeks or months, but then gets episodes of intense nausea and repeated vomiting lasting for hours to days? This description defines the symptom-based diagnosis for cyclic vomiting syndrome, a paroxysmal brain-gut disorder often related to migraine headaches and abdominal migraines. These intense episodes of nausea and pain leave the child feeling so awful, that they reject eating even during periods of wellness.

Once you recognize cyclic vomiting syndrome, there are medicines that prevent its return in almost every case. When episodes break through, they are treated by sedating the toddler so that there is no suffering. The toddler sleeps through the episode.

Are you saying that this is a 3 year old who vomits bile regularly? This symptom suggests that there may be a partial or intermittent anatomic obstruction in the gastrointestinal tract. Less likely, there may be a serious motility disorder causing backwards flow of intestinal contents. No wonder the child won't eat: it hurts! Your behavioral treatments will not work until you correct the anatomic or physiologic problem that is causing bile to back up and out.

This is exactly the kind of child who needs a motility study to determine what combination of motility, sensory, and arousal issues contribute to the feeding problems, and then treat with confidence based on pathophysiology. You should refer to my case series of similar kids in *J Pediatric Gastroenterology and Nutrition*, T Zangen et al "Gastrointestinal motility and sensory abnormalities may contribute to food refusal in medically fragile toddlers." 37:287-293, Sept, 2003.

Laparoscopic Nissen Fundoplication in Children: Is this a better procedure?

Continued

3. Allal H, Captier G, Lopez M, Forgues D, Galifer RB. Evaluation of 142 consecutive laparoscopic fundoplications in children: effects of the learning curve and technical choice. *J Pediatr Surg.* Jun 2001;36(6):921-926.
4. Graziano K, Teitelbaum DH, McLean K, Hirschl RB, Coran AG, Geiger JD. Recurrence after laparoscopic and open Nissen fundoplication: a comparison of the mechanisms of failure. *Surg Endosc.* May 2003;17(5):704-707.
5. Mattioli G, Sacco O, Gentilino V, et al. Outcome of laparoscopic Nissen-Rossetti fundoplication in children with gastroesophageal reflux disease and supraesophageal symptoms. *Surg Endosc.* Mar 2004;18(3):463-465.
6. Zeid MA, Kandel T, el-Shobary M, et al. Nissen fundoplication in infants and children: a long-term clinical study. *Hepato-gastroenterology.* May-Jun 2004;51(57):697-700.
7. Lima M, Bertozzi M, Ruggeri G, et al. Laparoscopic antireflux surgery in neurologically impaired children. *Pediatr Surg Int.* Feb 2004;20(2):114-117.
8. Steyaert H, Al Mohaidly M, Lembo MA, Carfagna L, Tursini S, Valla JS. Long-term outcome of laparoscopic Nissen and Toupet fundoplication in normal and neurologically impaired children. *Surg Endosc.* Apr 2003;17(4):543-546.
9. Hopkins MA, Stringel G. Laparoscopic Nissen fundoplication in children: a single surgeon's experience. *Jsls.* Oct-Dec 1999;3(4):261-266.
10. Powers CJ, Levitt MA, Tantoco J, et al. The respiratory advantage of laparoscopic Nissen fundoplication. *J Pediatr Surg.* Jun 2003;38(6):886-891.
11. Somme S, Rodriguez JA, Kirsch DG, Liu DC. Laparoscopic versus open fundoplication in infants. *Surg Endosc.* Jan 2002;16(1):54-56.

Food for Thought

By Lori L. Overland, M.S., CCC/SLP

(Continued from page 2)

show, the diagnosis of "feeding aversion" or "behavioral feeding problem" doesn't always adequately represent the issues.

A comprehensive feeding evaluation must include assessing motor and sensory skills. Adequate respiration and postural stability are your first considerations, since stability in the body will support mobility in the mouth. Then, assess oral phase skills, such as lip closure, tongue retraction, tongue bowling, tongue lateralization and tongue tip elevation.

A five-day baseline diet, analyzed in terms of taste, texture and temperature, should serve as an initial exploration of a client's sensory preferences. Focus your therapy plan on facilitating the motor skills children need to handle feeding. Make sure they slowly explore taste, texture and temperature variables, with only one change made at a time.

In Sarah's case, we changed the temperature of the food bolus while maintaining the taste and texture. If we had not been successful with that variable, we may have tried changing the taste (i.e., adding cinnamon to applesauce) while maintaining the texture and temperature.

Use sensory variables, such as taste and temperature, to facilitate changes in motor skills. As motor development occurs, a client will be better able to handle an increased variety of textures. The client will then become an active participant in sensory exploration and in the feeding interaction.

Lori L. Overland, M.S., CCC-SLP, is the clinical director of Sara R. Johnson and Associates in South Salem, NY. She presents CEU-approved sensory and feeding seminars and can be reached via e-mail at romotorlo@aol.com

Resource Center:

www.livingwithout.com

Living without is a magazine that provides support and education for those living with allergies or chemical sensitivities. A one year subscription which includes 4 issues will cost \$23.00. Their website includes sample articles, back issues and information on how to order.

If you have a good resource please email feedingnews@earthlink.net. We would love to include it in the newsletter.

Case by Case

by Cecilia J. Manno, MS, CCC/SLP, Private Practice,
Newtown, PA

Reason for referral: 6 yr. 4 month old boy dependent upon GT feedings for primary nutrition.

Diagnoses: Ex. 23 week old premie, Continued intubation since birth and ventilator dependent until 2 yrs. of age, Tracheal reconstructive surgery and decannulation at 4 yrs. of age, S/P BPD, NEC w/ colostomy x2, GERD, ROP w/ multiple laser surgeries, Grade II IVH, GT dependent with some PO intake, Hoarse voice

Swallowing: A recent laryngoscopy with bronchoscopy had been completed to evaluate J. F.'s vocal cords due to his hoarse voice and there had been question of airway protection. Results demonstrated mild laryngeal edema with 10% subglottic stenosis.

Gastrointestinal: JF has a history of GERD but has been off any GI medications since 4 yrs. of age. He was receiving five 8oz. boluses of Pediasure pushed by syringe daily as well as a half can of Pediasure PO with his morning cereal. During the feeding observation JF demonstrated voice changes and breathing changes with increased pharyngeal congestion and multiple throat clearings through the meal. He demonstrated limited PO intake, would rub his stomach, gagged with textured foods, was irritable and demonstrated increased burping.

Pulmonary: JF continues to receive Baclovent 2 puffs BID for question of asthma. Shallow breathing pattern.

Oral-Motor: There is slight facial asymmetry with better movement on the right side but no drooling. The tongue sits midline in the oral cavity but shifts to the right when asked to stick it out. There is decreased dissociation of the tongue and jaw and decreased gradation of the jaw with wide jaw excursions. Tonsils are 2+. During the feeding observation JF opens his mouth wide to accept the food, places it centrally on the tongue then transfers it to the right molars to munch. He uses a suck swallow pattern to transport the bolus. At times he would use liquid to help transfer the bolus through the pharynx. When asked to transfer the bolus to the left side he was much less efficient and more sensitive on that side.

He was noted to have increased audible breaths during this feeding with increased coughing and throat clearing up to 10 minutes after the meal.

Movement patterns were reduced with JF demonstrating a linear pattern of movement with little trunk rotation, limited upper trunk extension, shortened pectoralis muscles and a forward head position.

Behavior: JF was compliant in trying a small meal two times a day but would only take very limited amounts of food each time.

Treatment: A multidimensional approach was used consisting of manipulation of his GT regimen with his primary physician; improve his respiratory pattern to increase diaphragmatic breathing and productive cough, oral-motor treatment to improve symmetry of movement and transport pattern, to re-start GI medications (Zantac), to increase volume and variety of foods with table puree and soft textured and mashed foods and to provide therapeutic practice sessions for foods requiring more chewing.

Neurodevelopment treatment (NDT) was provided to increase trunk rotation, upper trunk extension and neck symmetry.

JF was at the 98% percentile for weight (53 1/2 lbs.) and after talking to his primary physician was felt that he could lose up to 7 lbs. and still be a good weight. We decreased his Pediasure by one can the first three weeks of treatment. GT feeding was changed to be run by pump over 45-60 minutes instead of given by syringe. Zantac was started with his Mom noting an increase in comfort during GT and PO feedings.

Motor therapy consisted of activities to increase trunk rotation, stretching to the pectoralis muscles, and upper trunk extension. Scar massage was done due to the many scars he had over the trunk and the binding of tissue beneath them. Kinesiotape was also used to place over the scars. Oral motor therapy consisted of stretching the labial elevator muscles,

(Continued on page 9)

Case by Case

by Cecilia J. Manno, MS, CCC/SLP, Private Practice,
Newtown, PA

(Continued from page 8)

exercises to shift the tongue side to side, exercises for jaw gradation then practice with chewable foods transitioning to a chew from munch pattern and swallowing with his lips together with a single bolus swallow.

As the cans of Pediasure were decreased the volume of his pureed table foods and mashed foods were increased. His weight was checked weekly. He was also drinking 2 cans of Pediasure as opposed to taking them by GT.

After 2 months of treatment he had lost 11/2 lbs., was taking 13-20 oz. food PO and still taking 4 1/2 cans Pediasure a day. By Aug. (2 months later) his weight was 52 lbs. and he was down to 3 cans Pediasure. He was eating 3 meals a day consisting of mashed and regular table foods and one meal of naturally occurring purees. His oral motor efficiency was much improved though he still had shortening of the left side of the neck and preferred to use the right side for chewing.

At this point some neck traction and stretching was done and Kinesiotaping was applied to the left side of the neck. In 2 weeks time JF demonstrated increased neck symmetry during eating. We also began to transition from Pediasure to Carnation Instant Breakfast and regular milk.

By the end of September (5 months of treatment) the GT feedings were stopped with JF taking all meals PO. Texture was primarily soft solids. Total weight lost was 5 lbs. being monitored by myself and his primary physician. We continued work for another 2 months to increase his jaw grading and tongue movement with foods to transition to higher textured foods. His weight continued to be monitored with and increase in weight gain gradually. After 6 months without any GT feedings and getting through the winter and several illnesses, JF's GT was removed.

Discussion: After 2 years of feeding treatment with very little progress JF made remarkable gains and was able to stop all GT feedings in 5 months. This was due primarily to beginning Zantac again to make him more comfortable; placing him back on the pump for his GT feedings instead of using a syringe to push them through; a weight cushion so that he could safely lose some weight during treatment with continued monitoring and the exercises to improve cough, motor skills and chewing efficiency.

Contact author at: cjmanno@macdialup.com

On the Research Front:

Alder EM, Williams FL, Anderson AS, Forsyth S, Florey Cdu V, van der Velde P. What influences the timing of the introduction of solid food to infants?

British Journal of Nutrition. 2004 Sep;92(3):527-31.

This study looked at the factors which may influence the timing of the introduction of solid food to infants. The early introduction of solids was found to be associated with: the opinions of the infant's maternal grandmother; living in a deprived area; personal disagreement with the advice to wait until the baby was 4 months; lack of encouragement from friends to wait until the baby was 4 months; and receiving free samples of baby food. Some of the factors influencing a woman's decision to introduce solids are amenable to change, and these could be targeted in educational interventions.

Schreck KA, Williams K, Smith AF. A comparison of eating behaviors between children with and without autism. *J Autism Dev Disord.* 2004 Aug;34(4):433-8.

This study compared caregiver reports of eating problems of children with and without autism on a standardized questionnaire. Items pertaining to food refusal and acceptance patterns as well as food presentation were addressed. Caregivers were also asked to complete a food inventory that indicated the number of foods eaten within each food group for both the child and the family. Results indicated children with autism have significantly more feeding problems and eat a significantly narrower range of foods than children without autism.

© all rights reserved.

Hiro Publishing
3106 Lincoln Street
Salt Lake City, UT 84106
www.feedingnews.com
phone: 801-599-8250
Email: feedingnews@earthlink.net

Special for Feeding Therapists and Professionals!

Questions, comments, submissions, and suggestions are all welcome. Please be vocal, the hope is that this forum will be educational and will help to connect us as professionals working together.



On the Research Front:

Lanes R, Soros A. Decreased final height of children with growth deceleration secondary to poor weight gain during late childhood. J Pediatr. 2004 Jul;145(1):128-30.

Eighteen healthy, short children with normal growth during most of their childhood were evaluated after a sustained fall in weight and reduced linear growth. Growth was followed after nutritional counseling until final height. This report demonstrates the need for an appropriate weight gain in growing children as prolonged caloric restriction will affect growth velocities long term and may lead to reduced final heights.

Vaiman M, Segal S, Eviatar E. Surface electromyographic studies of swallowing in normal children, age 4-12 years. Int J Pediatr Otorhinolaryngol. 2004 Jan;68(1):65-73.

Normative data for duration and amplitude of muscle activity during single swallowing and continuous drinking are established for healthy children. The duration of muscle activity during swallows and drinking in all tests showed decrease with the age. Surface EMG of swallowing is a simple and reliable noninvasive method for screening swallowing. The data can be used for evaluation of complaints and symptoms, as well as for comparison purposes in pre- and postoperative stages and in electromyography (EMG) monitoring. These parameters represent normal deglutition, and can be used to identify abnormalities in pediatric patients, and provide a basis for comparison of swallowing performance, both within and between patients.

Thoyre SM, Brown RL. Factors contributing to preterm infant engagement during bottle-feeding. Nurs Res. 2004 Sep-Oct;53(5):304-13.

The ability of the preterm infant to maintain engagement during bottle-feeding cannot be explained by characteristics of the infant or by the prefeeding condition of the infant alone. Rather, engagement is co-regulated by the caregiver and the infant throughout the feeding. Strategies to assist infants in maintaining physiologic stability during bottle-feeding and further study of effective and contingent caregiver feeding behaviors are needed.

This material is provided for informational and educational purposes only; it does not contain specific medical advice. If you have specific health questions or problems, consult a health care professional for personal medical advice.